

INTERPRETATION GUIDE

BOND MMR ANTIBODY PANEL



Advancing Cancer Diagnostics
Improving Lives

CONTENTS

| | |
|--|----|
| Introduction | 3 |
| Scientific and Clinical Rationale for MMR Protein Testing | 3 |
| Assay Description..... | 4 |
| Interpretation Guidelines..... | 4 |
| Evaluation of Hematoxylin and Eosin (H&E) Stained Slides | 4 |
| Evaluation of Negative Isotype Controls | 4 |
| Evaluation of MMR Antibody Stained Slides | 4 |
| Interpretation Summary | 6 |
| Representative Images & Staining Description | 7 |
| MMR Protein Expression in Non-neoplastic Tissue | 7 |
| MLH1: CRC Cases With Intact versus Loss MMR Protein Expression, Side-by-Side Comparison..... | 8 |
| MSH2: CRC Cases With Intact versus Loss MMR Protein Expression, Side-by-Side Comparison..... | 9 |
| MSH6: CRC Cases With Intact versus Loss MMR Protein Expression, Side-by-Side Comparison..... | 10 |
| PMS2: CRC Cases With Intact versus Loss MMR Protein Expression, Side-by-Side Comparison..... | 11 |
| Challenging Cases..... | 13 |
| Equivocal/Weak Nuclear Staining..... | 13 |
| Heterogeneous Staining Patterns..... | 14 |
| Cytoplasmic Background | 15 |
| References..... | 16 |
| BOND MMR Antibody Panel Product Information..... | 16 |

INTRODUCTION

Lynch Syndrome (LS) is an autosomal dominant hereditary cancer predisposition caused by germline mutation in one of four genes that encode DNA Mismatch Repair (MMR) proteins - MLH1, MSH2, MSH6, and PMS2. MMR proteins play a vital role in maintaining genome integrity during the cell cycle. Disruption of their function leads to expansion of homopolymeric nucleotide repeats, or microsatellite instability (MSI), throughout the genome and an accumulation of mutations in genes that promote carcinogenesis. Lynch Syndrome is associated with a 50-70% lifetime risk of colorectal cancer (CRC) and an increased risk of other malignancies therefore identification of such high-risk patients is vital both for the individuals concerned and for their relatives who may also have inherited LS mutations.

Sporadic CRC can be MMR deficient through biallelic MMR gene mutation and/or locus methylation without germline MMR gene mutation, indeed the majority of MMR-deficient CRC arise from somatic rather than germline mutations. Current cancer treatment guidelines indicate that all newly diagnosed CRCs should be screened for MMR status because the results have implications for estimating the patient's prognosis in both sporadic and LS associated CRC. MMR screening can also provide a preliminary diagnosis for identifying patients with LS which enables the selection of proper cancer surveillance regimens and therapies, and for counseling the patient's family for risk of cancer.

SCIENTIFIC AND CLINICAL RATIONALE FOR MMR PROTEIN TESTING

As MMR proteins play an integral role in the fidelity of DNA replication, they are present at variable levels in the nuclei of all human cells, particularly in tissues undergoing rapid renewal.

Germline or somatic mutation and/or epigenetic silencing of any MMR gene usually results in loss of the particular protein it encodes. Because heterodimerization of MMR proteins is linked to complex stability, loss of one protein can lead to loss of its partner; loss of MSH2 can lead to simultaneous loss of MSH6, and loss of MLH1 can lead to simultaneous loss of PMS2, although loss of MSH6 or PMS2 does not always lead to loss of MSH2 or MLH1. Immunohistochemical (IHC) testing of CRC samples using antibodies specific for each of the four MMR proteins can thus be used to identify MMR-deficient tumors and as a preliminary screening method for Lynch Syndrome. Whether associated with Lynch Syndrome or not, stage-matched, MMR-deficient CRC have a better prognosis than MMR-proficient CRC and consequently, the 2017 ASCO/CAP Guidelines (Molecular Biomarkers for the Evaluation of Colorectal Cancer¹) state that "Diagnosis of Lynch syndrome is important as active management of cancer risks has been demonstrated to benefit gene mutation carriers" and also that "testing for dMMR can be performed by immunohistochemistry for the four MMR proteins (MLH1, MSH2, PMS2, and MSH6) or by MSI DNA-based testing."

ASSAY DESCRIPTION

MLH1, MSH2, MSH6, and PMS2 antibodies can be used for the identification of their target MMR proteins in slide-mounted sections from samples of formalin-fixed, paraffin-embedded (FFPE) tissue by light microscopy.

The four MMR antibodies are intended for use as a panel; loss of one or more of these proteins in the nuclei of neoplastic cells but not non-neoplastic cells is indicative of tumor MMR deficiency.

The BOND Ready-to-Use (RTU) MMR primary antibodies consist of monoclonal antibodies produced by the ES05, 79H11, EP49, and EP51 clones which are specific for the MMR proteins MLH1, MSH2, MSH6, and PMS2 respectively. These four antibodies are compatible with the BOND-MAX and BOND-III automated staining platforms using the BOND Refine Detection (DS9800) and are provided in 7 mL BOND RTU primary antibody formats with names and product codes as follows:

| CODE | NAME | CONFIGURATION | RETRIEVAL |
|----------|--|-------------------|-----------|
| PA0988-U | MLH1 (Mismatch Repair Protein) (ES05) | BOND Ready-to-Use | ER1 30 |
| PA0989-U | MSH2 (Mismatch Repair Protein) (79H11) | BOND Ready-to-Use | ER2 20 |
| PA0990-U | MSH6 (Mismatch Repair Protein) (EP49) | BOND Ready-to-Use | ER2 20 |
| PA0991-U | PMS2 (Mismatch Repair Protein) (EP51) | BOND Ready-to-Use | ER2 20 |

INTERPRETATION GUIDELINES

Evaluation of Hematoxylin and Eosin (H&E) Stained Slides

H&E stained slides are used to assess the overall quality of the tissue sample for each case. An assessment should be completed regarding the quality and quantity of the tumor content of the CRC sample. Cases should be voided if there is insufficient tumor (less than 50 viable tumor cells) available to score or if the sample is poorly fixed or otherwise of insufficient quality that renders interpretation of the case impossible.

Evaluation of Negative Isotype Controls

Negative isotype control slides are used to gauge the impact of non-specific staining that may arise from elements within the system other than the primary antibody. The Negative Mouse Isotype (PA0996-U) control slide should be used in the assessment of PA0988-U and PA0989-U and the Negative Rabbit Isotype (PA0777-U) control with PA0990-U and PA0991-U. Weak nuclear staining in occasional cells in a minority of cases may be observed. This, along with any background staining, should be taken into consideration when assessing the associated test slides. If the staining in a negative isotype control slide is of an intensity sufficient to adversely affect the interpretation of the associated test slides, then these slides should be voided.

Evaluation of MMR Antibody Stained Slides

The status for any of the four MMR proteins is assigned as follows:

INTERPRETATION GUIDELINES

A status of MMR protein “Intact” is assigned to cases with:

- Unequivocal nuclear staining in viable tumor cells in association with appropriate nuclear staining of non-neoplastic (internal control) cells* (see Figures 2A, 3A, 4A, 5A).
- Heterogeneous nuclear staining in viable tumor cells in association with appropriate nuclear staining of non-neoplastic (internal control) cells*. Heterogeneity of MMR protein expression can present in various patterns that are described in more detail in the Representative Images section (Figures 7 and 8).**

A status of MMR protein “Loss” is assigned to cases with:

- Unequivocal absence of nuclear staining in viable tumor cells in association with appropriate nuclear staining of non-neoplastic (internal control) cells* (see Figures 2B, 3B, 4B, 5B).
- Equivocal (eg. cytoplasmic or weak nuclear) staining in viable tumor cells in association with appropriate nuclear staining of non-neoplastic (internal control) cells* (see Figure 6).

*Appropriate internal positive controls can include nuclear staining in:

- Normal colonic epithelium, with staining typically strongest in the crypts and fading in intensity towards the luminal surface.
- Infiltrating lymphocytes with variable levels of staining intensity, plus mantle cells and proliferating germinal center cell lymphocytes.
- Fibroblasts with variable levels of staining intensity.
- Nerve cells with moderate to strong staining intensity.

**Well demarcated areas of loss or weak nuclear protein expression in the presence of appropriate internal control staining have been reported in cases with causative genetic deficiencies.^{2,3,4} In the clinical setting, some patterns of heterogeneous expression of one or more MMR proteins may prompt further investigation by molecular methodologies.

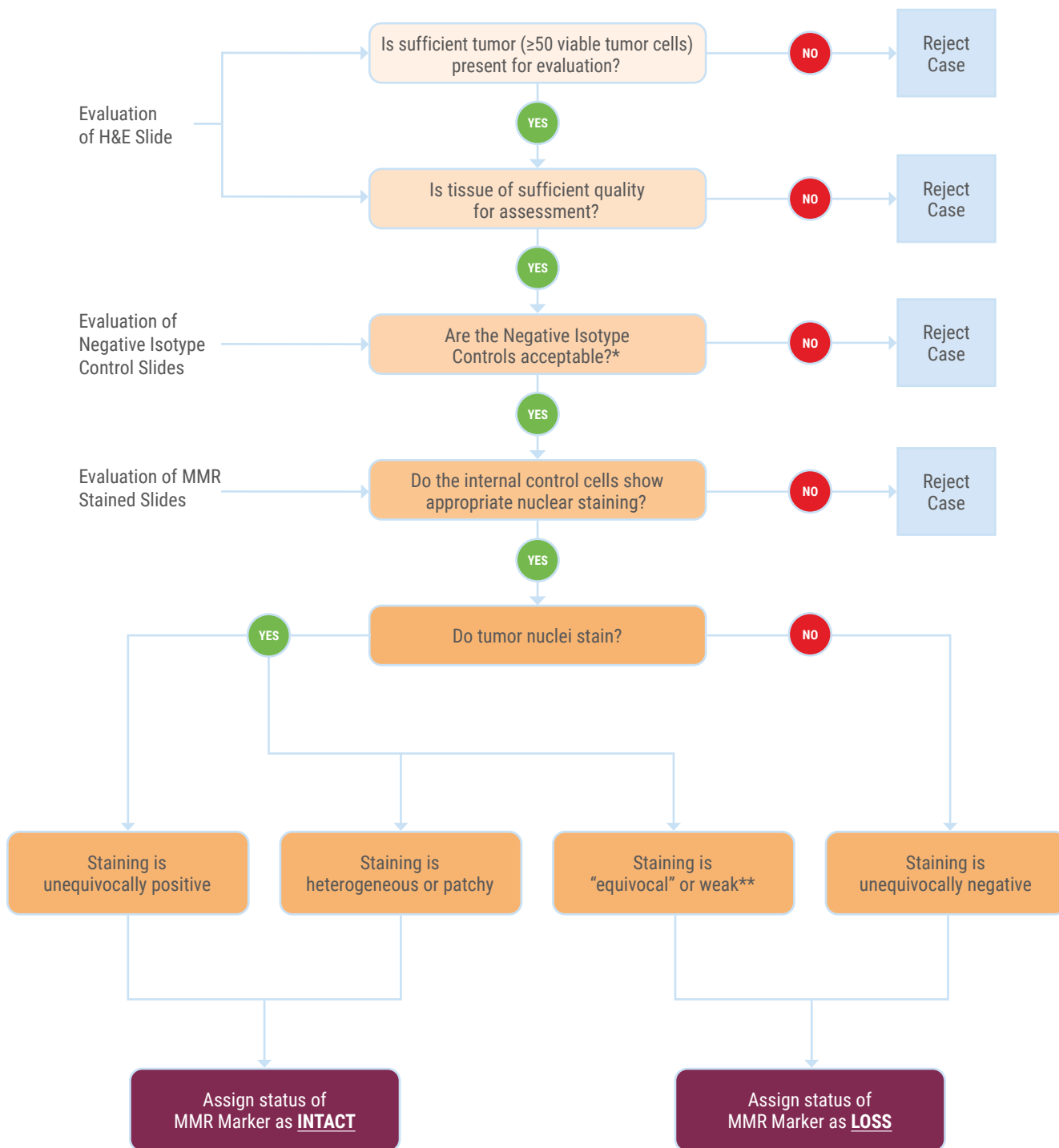
An absence of or equivocal staining in internal positive control cells, or cytoplasmic background staining that masks the nuclear staining should be considered as a failure of the assay.

The staining of MMR protein expression, as detailed in the Representative Images and Staining Description section, can be broken down into four main categories (note - all assume clear positive staining of control cells within tissue):

The MMR protein status for each IHC marker shall be assigned following the Interpretation Summary.

| OBSERVATION | INTERPRETATION |
|--|----------------|
| Unequivocally Positive Tumor Staining | MMR INTACT |
| Heterogeneous or Patchy Nuclear Staining | MMR INTACT |
| Very Weak Nuclear Staining | MMR LOSS |
| Unequivocally Negative | MMR LOSS |

INTERPRETATION SUMMARY



* Any staining seen in the Negative Isotype Controls should be taken into account when interpreting the MMR antibody stained test sections. If any staining is judged to be of sufficient intensity to adversely affect the interpretation of the test sections then this should be classed as unacceptable and the case voided.

** Weaker than internal positive control cells

REPRESENTATIVE IMAGES & STAINING DESCRIPTION

MMR Protein Expression in Non-neoplastic Tissue

In the normal colorectal epithelium, MMR proteins are expressed most strongly in cells in the crypts and the intensity fades as the cells migrate towards the lumen (Figures 1A and 1B). They are also expressed to a variable extent in the nuclei of infiltrating lymphocytes in the lamina propria and throughout the sub-mucosa, the mucosal-associated lymphoid tissue (particularly the germinal centers) and in nerve cells. This widespread expression of MMR proteins in the nuclei of normal cells provides an internal control when assessing CRC cases (Figures 2A/2B thru 5A/5B).

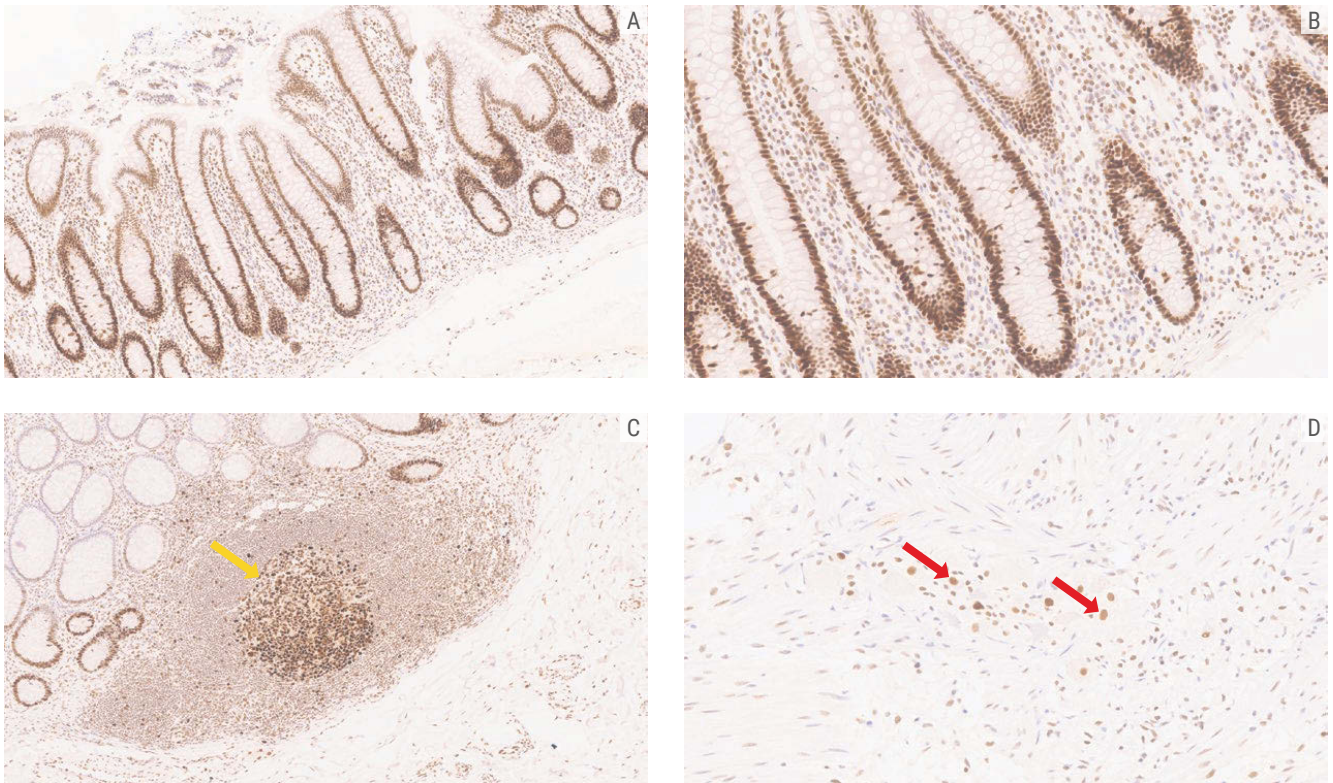


Figure 1. Representative images of MMR protein expression in normal colon tissue

A. MSH2 expression in normal colonic mucosa (4x)

B. Higher power (10x) image of the same tissue shown in A

C. MSH6 expression on mucosal-associated lymphoid tissue with stronger staining in the cells of the germinal centers (yellow arrow) (4x)

D. PMS2 expression in the nuclei of nerve cells (red arrows) in the myenteric plexus (20x)

REPRESENTATIVE IMAGES & STAINING DESCRIPTION

MLH1: CRC Cases With Intact versus Loss MMR Protein Expression, Side-by-Side Comparison

Intact MMR protein status is characterized by the presence of nuclear staining in viable tumor cells in association with appropriate nuclear staining of non-neoplastic (internal control) cells.

MMR protein loss status is characterized by the absence of nuclear staining of viable tumor cells in association with appropriate nuclear staining of non-neoplastic (internal control) cells.

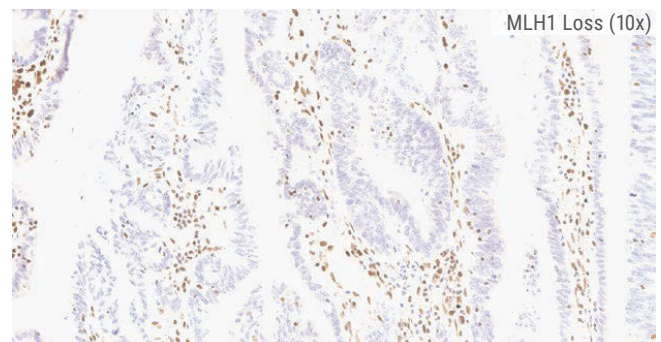
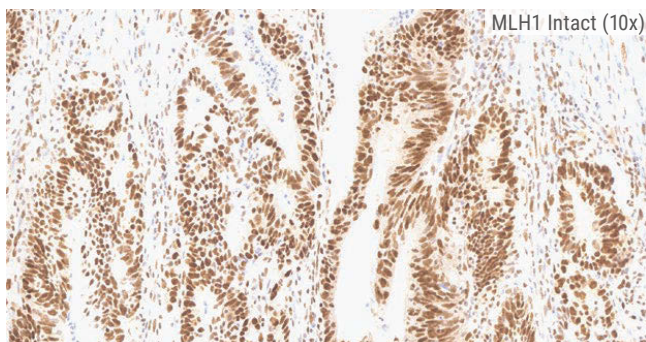
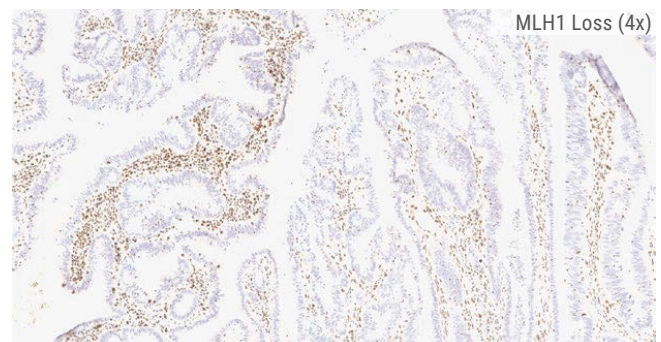
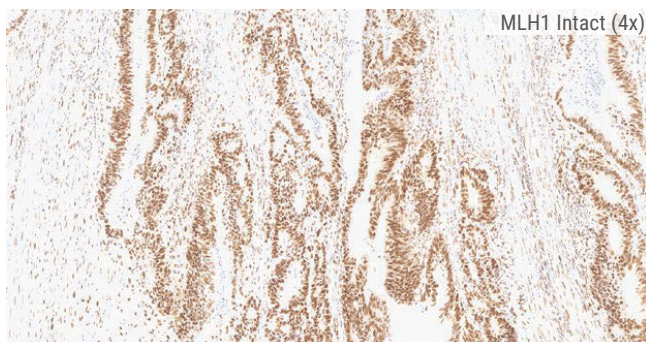
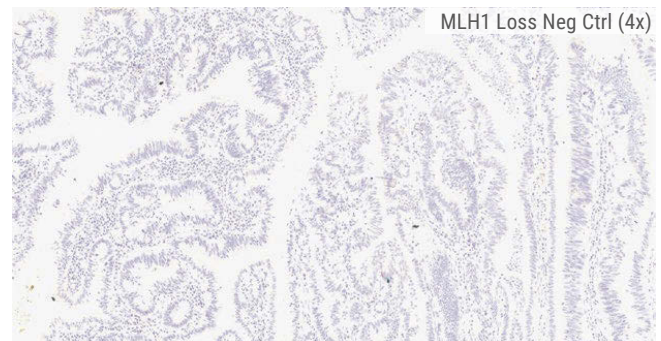
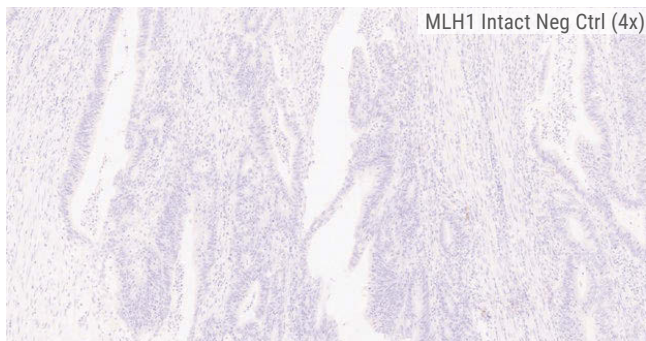
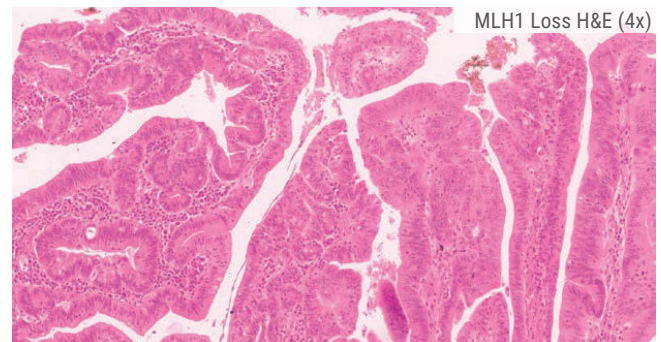
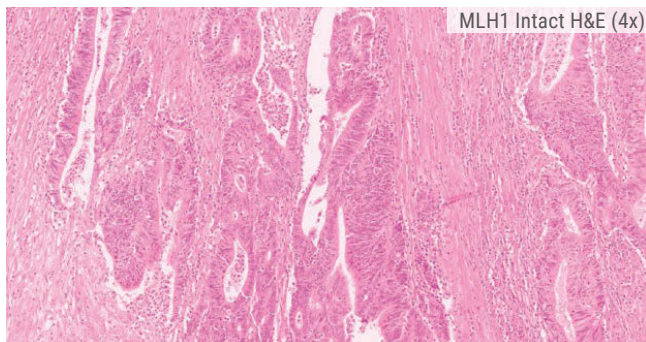


Figure 2A. MLH1 Intact Case

Figure 2B. MLH1 Loss Case

REPRESENTATIVE IMAGES & STAINING DESCRIPTION

MSH2: CRC Cases With Intact versus Loss MMR Protein Expression, Side-by-Side Comparison

Intact MMR protein status is characterized by the presence of nuclear staining in viable tumor cells in association with appropriate nuclear staining of non-neoplastic (internal control) cells.

MMR protein loss status is characterized by the absence of nuclear staining of viable tumor cells in association with appropriate nuclear staining of non-neoplastic (internal control) cells.

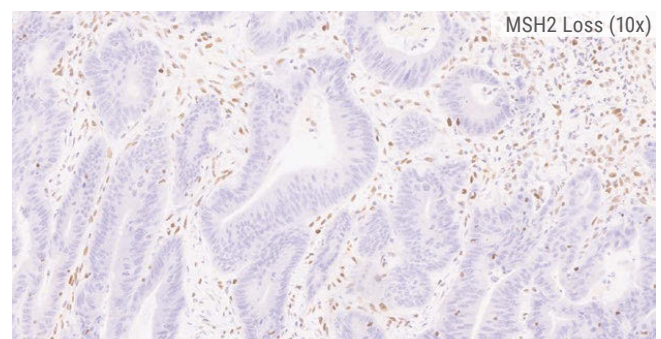
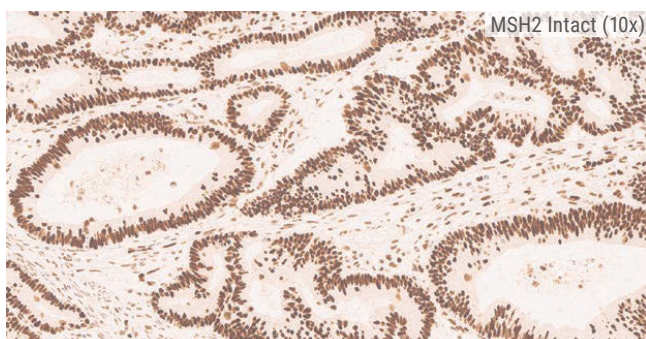
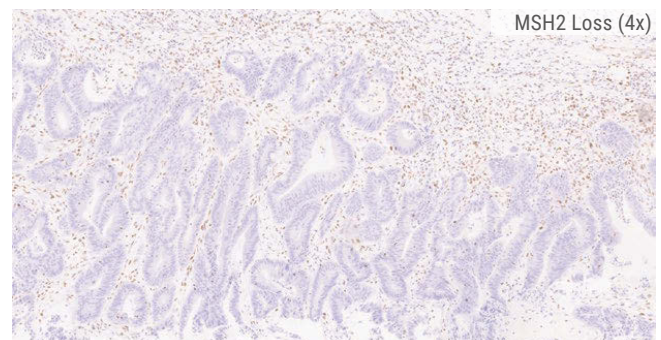
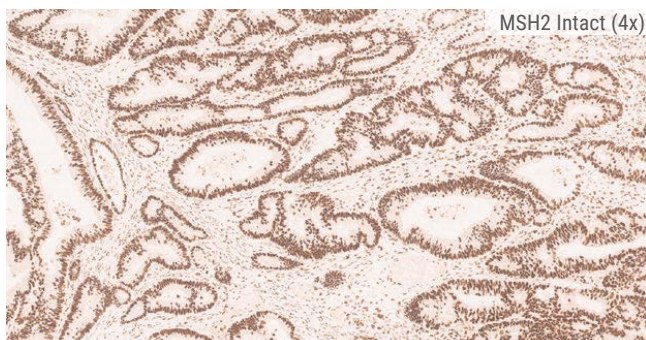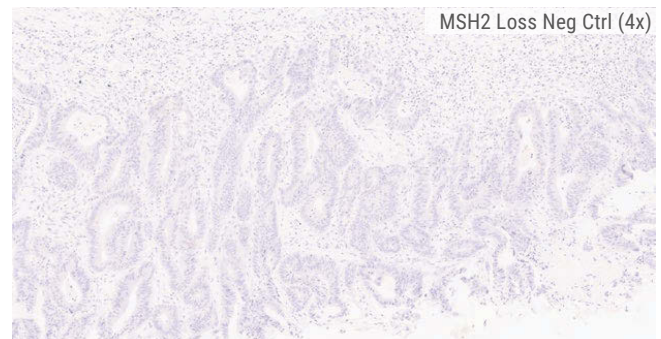
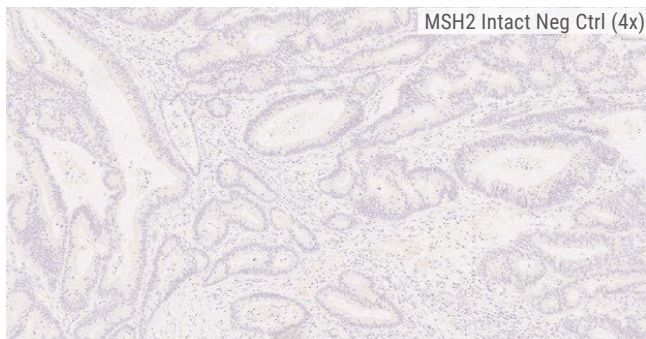
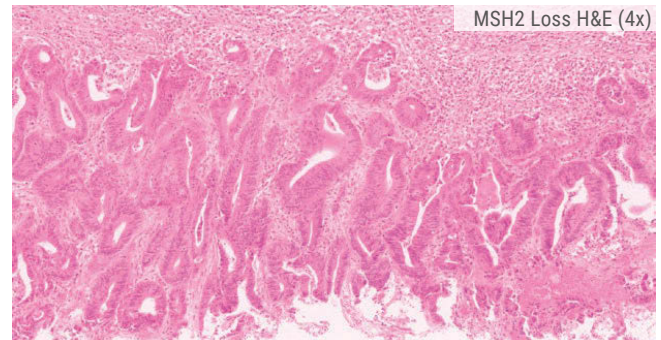
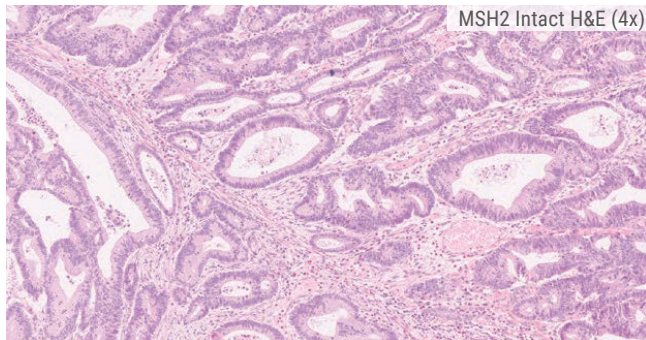


Figure 3A. MSH2 Intact Case

Figure 3B. MSH2 Loss Case

REPRESENTATIVE IMAGES & STAINING DESCRIPTION

MSH6: CRC Cases With Intact versus Loss MMR Protein Expression, Side-by-Side Comparison

Intact MMR protein status is characterized by the presence of nuclear staining in viable tumor cells in association with appropriate nuclear staining of non-neoplastic (internal control) cells.

MMR protein loss status is characterized by the absence of nuclear staining of viable tumor cells in association with appropriate nuclear staining of non-neoplastic (internal control) cells.

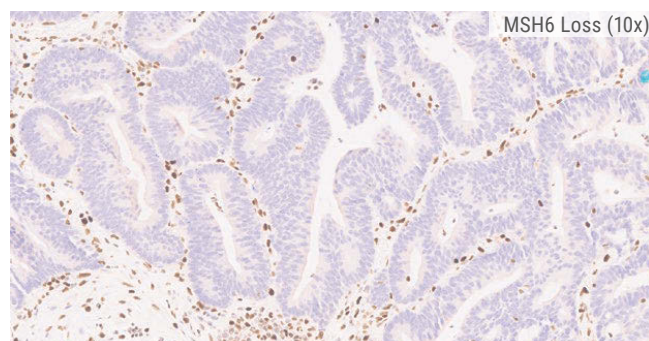
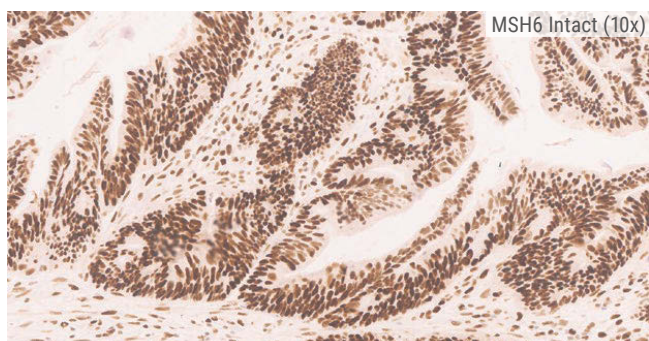
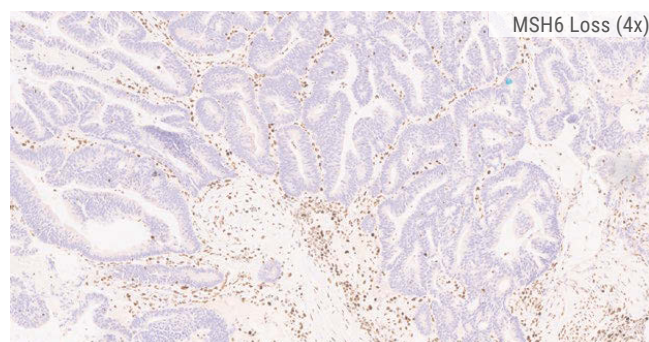
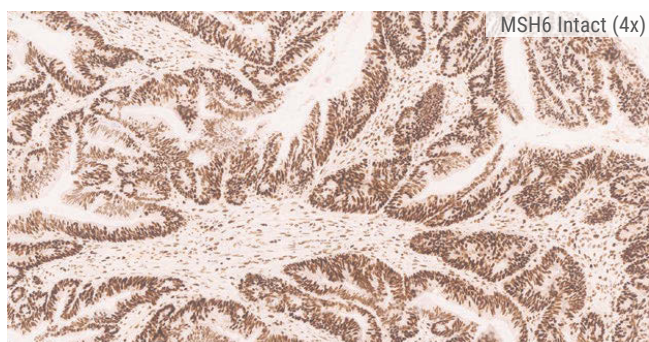
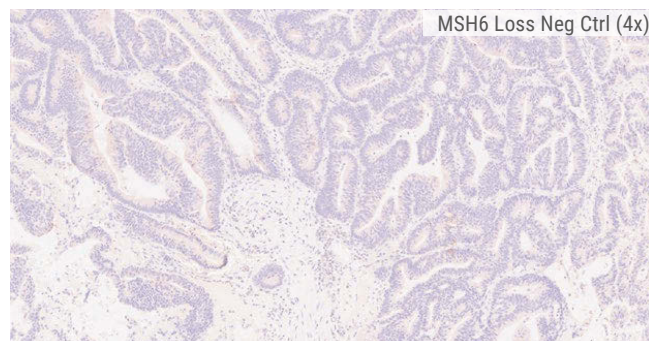
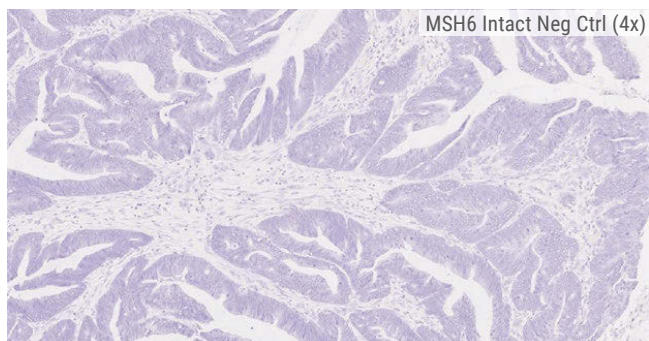
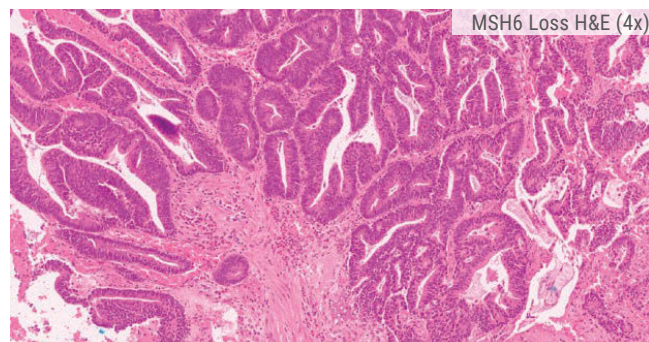
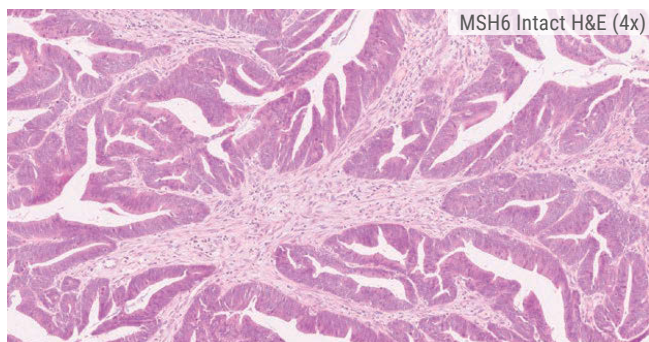


Figure 4A. MSH6 Intact Case

Figure 4B. MSH6 Loss Case

REPRESENTATIVE IMAGES & STAINING DESCRIPTION

PMS2: CRC Cases With Intact versus Loss MMR Protein Expression, Side-by-Side Comparison

Intact MMR protein status is characterized by the presence of nuclear staining in viable tumor cells in association with appropriate nuclear staining of non-neoplastic (internal control) cells.

MMR protein loss status is characterized by the absence of nuclear staining of viable tumor cells in association with appropriate nuclear staining of non-neoplastic (internal control) cells.

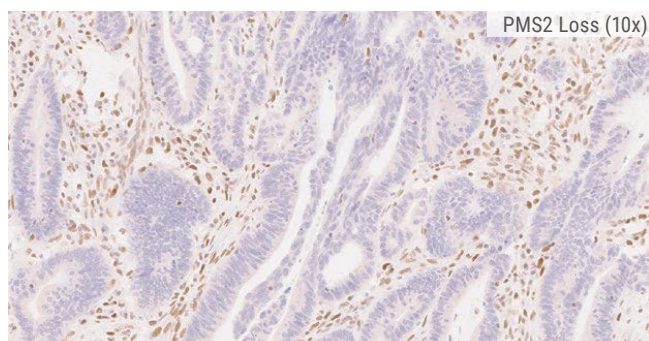
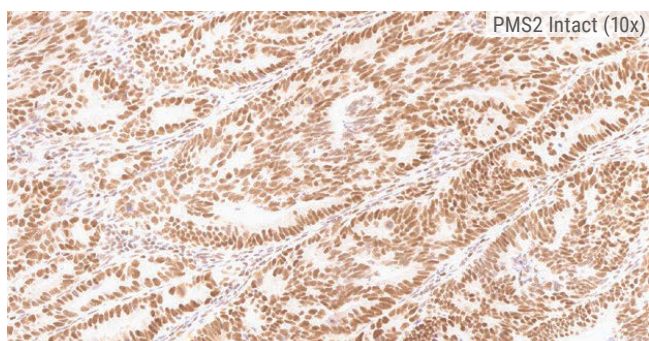
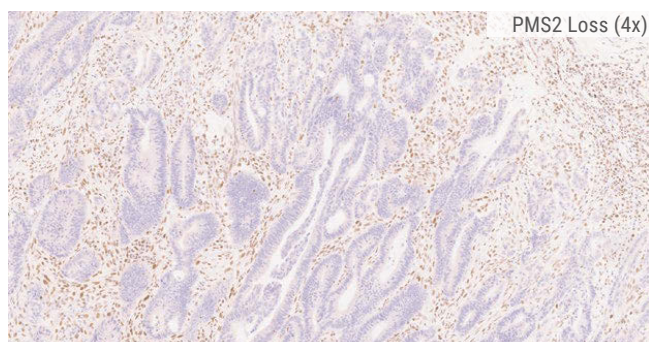
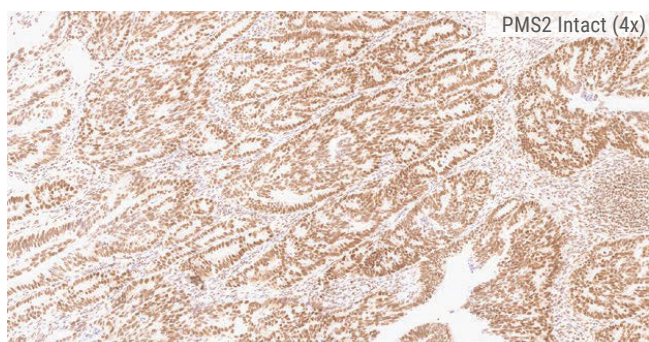
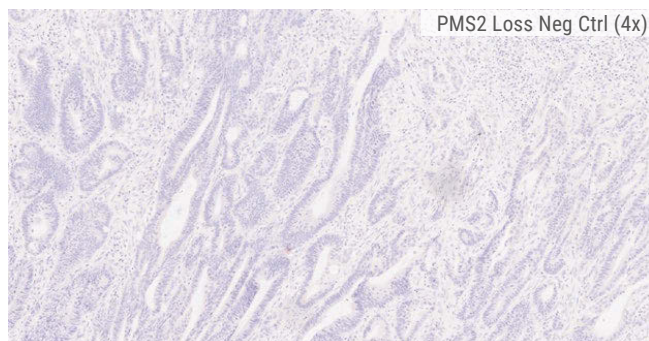
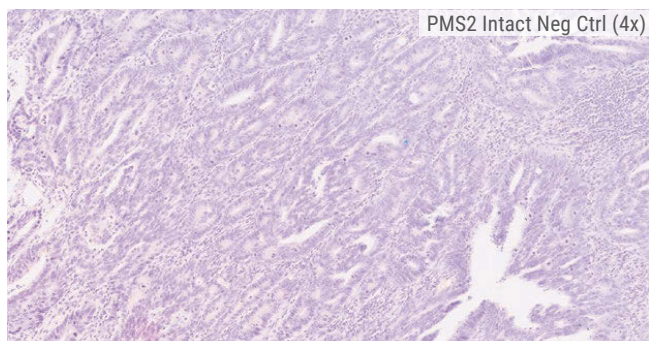
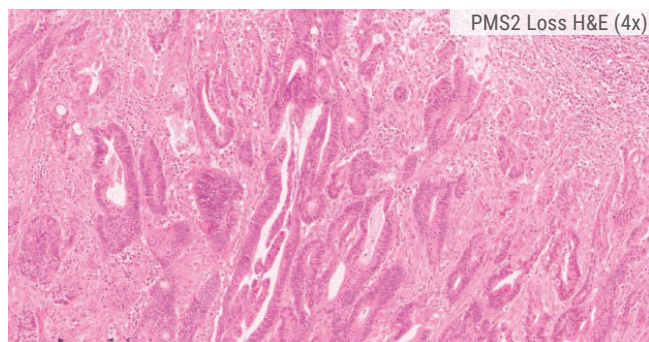
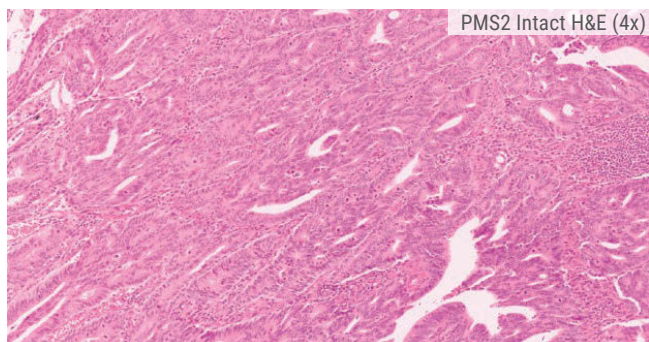


Figure 5A. PMS2 Intact Case

Figure 5B. PMS2 Loss Case

CHALLENGING CASES

In the majority of CRC cases, a binary decision can be made on the status of each MMR protein; either expression is uniformly intact (Figures 2A, 3A, 4A, 5A) or completely absent, throughout the whole tumor (Figures 2B, 3B, 4B, 5B). Occasionally, however, interpretation can be more challenging due to the following factors:

- **Equivocal/Weak Nuclear Staining**

Some CRC cases exhibit weak MMR protein in their tumor nuclei. In accordance with the Decision Summary, loss status in such cases is confirmed where any such staining is weaker than that seen in the positive internal control cell nuclei.

- **Heterogeneous Staining Patterns**

Occasionally, CRC cases will exhibit a heterogeneous pattern of staining that can be challenging to interpret. Heterogeneous patterns of MMR protein expression can potentially be difficult to distinguish from artifactual loss of staining intensity arising from inadequate fixation and processing or uneven staining arising from technical issues. The presence of positively stained infiltrating cells can aid in the identification of genuine heterogeneity. While heterogeneous expression patterns are classified as intact for MMR status, they have sometimes been associated with causative genetic abnormalities.^{2,3,4} Therefore, in the clinical setting some heterogeneous staining patterns (Figure 8) may warrant further investigation via MSI or molecular screening.

- **Background Staining**

Non-specific background may be seen in some samples. Where this occurs, comparison between the non-specific background and the corresponding area of the appropriate Negative Isotype Control should be made. Staining seen in the Negative Isotype Control needs to be taken into consideration when interpreting the staining in the test slide. Cytoplasmic background should be ignored during interpretation except in cases where it masks the nuclear staining; then the sample should be voided and the test repeated.

- **Artifacts**

Challenges to interpretation can arise from artifacts introduced by pre-analytical factors, particularly suboptimal sample fixation, processing, or microtomy. When factors such as fixation gradient staining or microtomy artifacts impact staining and interfere with the interpretation of MMR protein status, the sample should be voided and the test repeated.

Representative images of some of these factors are illustrated in the following pages.

CHALLENGING CASES

Equivocal/Weak Nuclear Staining

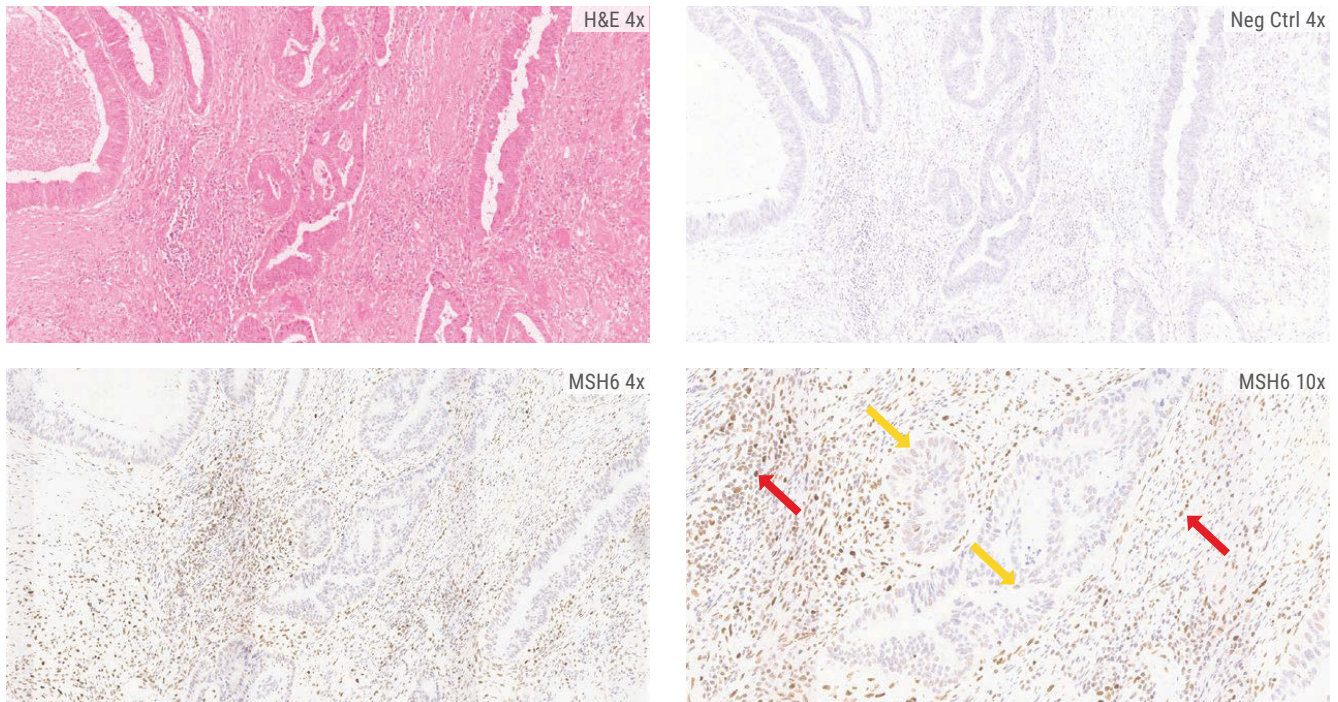


Figure 6. CRC case showing weak nuclear staining (yellow arrows) for MSH6. This staining, however, is markedly weaker than that seen in the normal positive control nuclei (red arrows) and this case is therefore classified as MSH6 Loss.

CHALLENGING CASES

Heterogeneous Staining Patterns

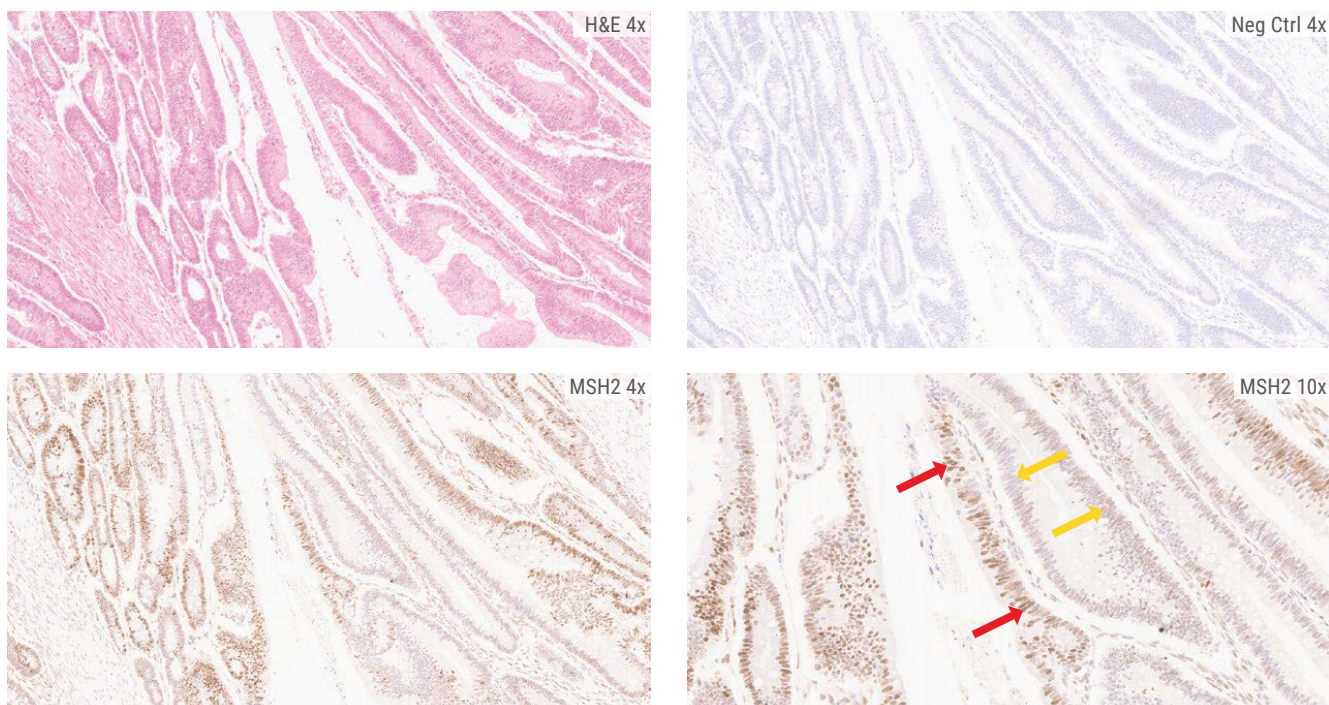


Figure 7. CRC case with a heterogeneous pattern of staining for MSH2. In some tumor nuclei, the MSH2 protein expression is extremely weak or completely absent (yellow arrows), whereas in others the staining is strong (red arrows). This mixed heterogeneous staining pattern is classified as MSH2 protein intact.

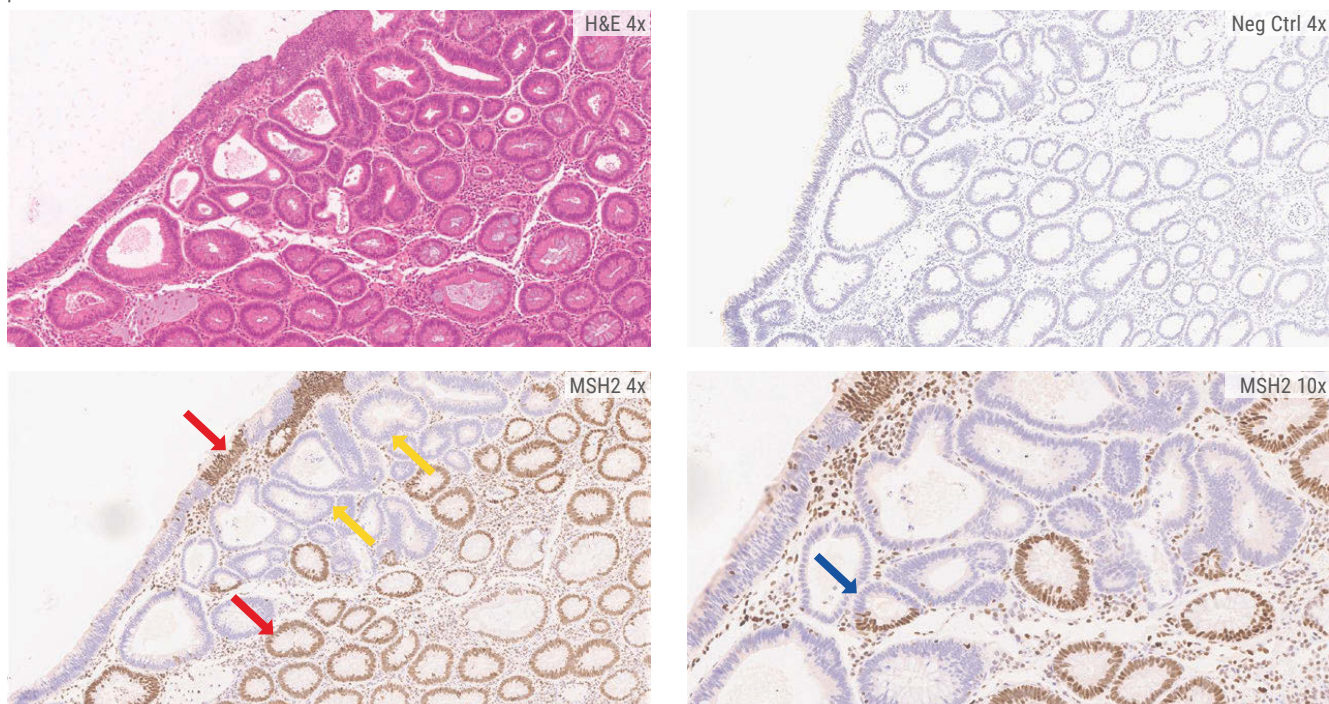


Figure 8. CRC case with a heterogeneous interglandular loss pattern where some areas have complete loss of MSH2 expression (yellow arrows), and others have normal staining (red arrows). An area of intraglandular loss can also be seen in the higher power image (blue arrow). While strict interpretation using the Decision Summary would define the sample as intact for MSH2, in the clinical setting such a staining pattern may warrant further investigation.

CHALLENGING CASES

Cytoplasmic Background

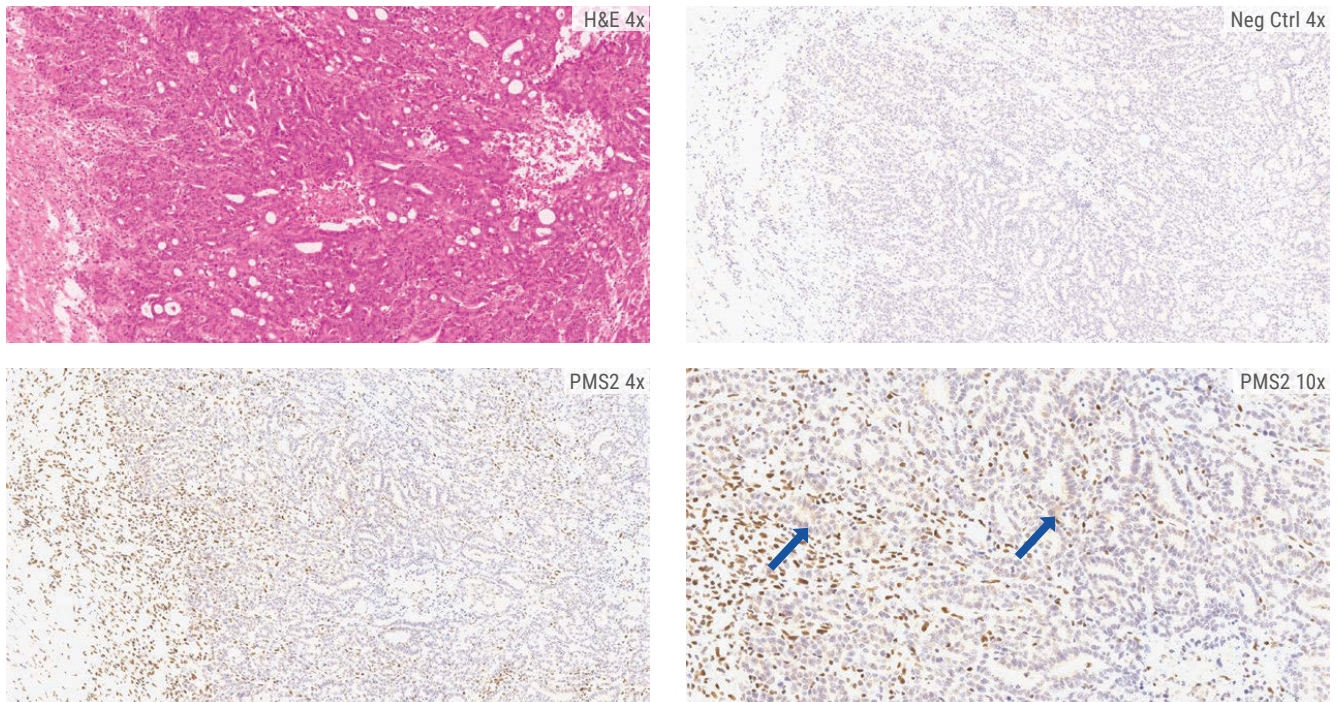


Figure 9. In this PMS2 loss case, there is some weak cytoplasmic background staining that does not mask the cell nuclei. This should not influence the interpretation of the protein status as the tumor nuclei are still negative in the presence of the internal positive control staining.

REFERENCES

1. Sepulveda AR, et al. Molecular biomarkers for the evaluation of colorectal cancer (Guideline from the American Society for Clinical Pathology, College of American Pathologists, Association for Molecular Pathology, and American Society of Clinical Oncology). Archives of Pathology Laboratory Medicine (2017): 142; 625-657.
2. Muller A, et al. Challenges and pitfalls in HNPCC by microsatellite analysis and immunohistochemistry. Journal of Molecular Diagnostics (2004): 6:4; 308-314.
3. Joost P, et al. Heterogeneous mismatch-repair status in colorectal cancer. Diagnostic Pathology (2014): 9; 126.
4. Marino FZ, et al. Microsatellite status detection in gastrointestinal cancers: PCR/NGS is mandatory in negative/patchy MMR immunohistochemistry. Cancers (2022), 14, 2204. <https://doi.org/10.3390/cancers14092204>

BOND MMR ANTIBODY PANEL PRODUCT INFORMATION

| CODE | NAME | CONFIGURATION | RETRIEVAL |
|----------|--|-------------------|-----------|
| PA0988-U | MLH1 (Mismatch Repair Protein) (ES05) | BOND Ready-to-Use | ER1 30 |
| PA0989-U | MSH2 (Mismatch Repair Protein) (79H11) | BOND Ready-to-Use | ER2 20 |
| PA0990-U | MSH6 (Mismatch Repair Protein) (EP49) | BOND Ready-to-Use | ER2 20 |
| PA0991-U | PMS2 (Mismatch Repair Protein) (EP51) | BOND Ready-to-Use | ER2 20 |

LEICA BIOSYSTEMS IS AN INTERNATIONAL COMPANY WITH A STRONG NETWORK OF WORLDWIDE CUSTOMER SERVICES
For detailed contact information on your nearest sales office or distributor please visit our website: [LeicaBiosystems.com](https://www.LeicaBiosystems.com)